

# Axillary Lymph Nodal Metastasis from Carcinoma of Unknown Primary (CUPAx)- An Orphan Disease

RENUKA BANGALORE NAGARAJ<sup>1</sup>, MD KHURSID ALAM ANSARI<sup>2</sup>

CC BY-NC-ND

## ABSTRACT

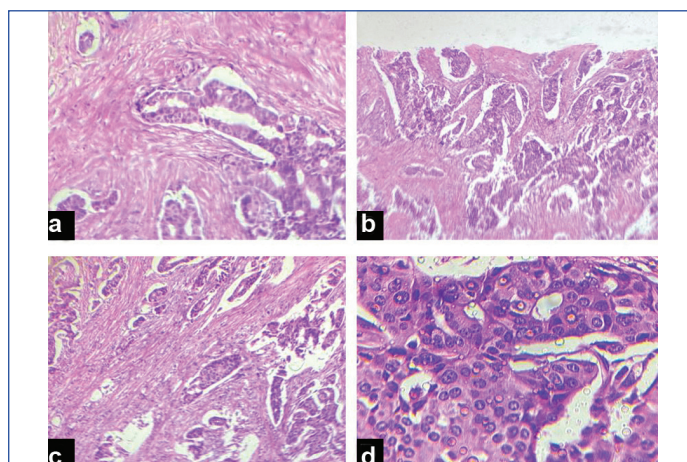
Metastasis to axillary lymph node occurs in adenocarcinoma or poorly differentiated carcinoma, and is a rare clinical entity that needs to be understood for management and its clinical outcome. The present case is of 72-year-old female patient who had a metastatic nodule in the axilla. No breast mass was palpable. Histology identified as metastatic adenocarcinoma, however mammography and Ultrasound Sonography test (USG) failed to detect the primary tumour. Immunohistochemistry showed that the excised lymph node was positive for Estrogen Receptor (ER) and negative for Progesterone Receptor (PR), suggesting the breast as the site for the primary tumour. Since the patient refused surgery, she was under follow-up for eight months. Now, she presented with recurrence of similar axillary swelling for two months.

**Keywords:** Adenocarcinoma, Breast, Estrogen receptor, Immunohistochemistry

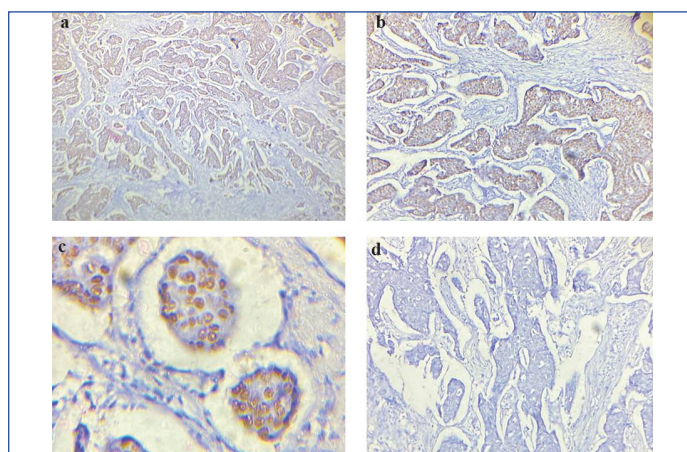
## CASE REPORT

A 72-year-old woman reported with a chief complaint of a painful swelling in the right axilla since one year. The swelling was 3.7×2.6 cm in size [Table/Fig-1]. Clinically, no mass was palpable in the right breast and no nipple discharge was seen. No signs of abnormality were found on ultrasonography and mammography. The patient underwent ultrasound guided Fine Needle Aspiration and it was reported as suspicious of atypical cells however biopsy was needed to confirm the diagnosis. The patient underwent excision [Table/Fig-2] and the tumour was sent for histopathological examination which revealed presence of ductular epithelial cells forming glandular pattern seen in desmoplastic stroma. Histopathological Examination (HPE) did not show infiltrative growth pattern involving dermis. Primary eccrine carcinoma was ruled out as the lesion did not have ulceration and was confined to axilla instead of head and neck. A complete workup including ultrasonography, computed tomography, oesophageal gastrography, and barium enema was done which was negative. Serum levels of CEA, CA-125, CA19-9, CA015-3 and Alfa Fetoprotien (AFP) were within normal limits. Estrogen Receptor analysis of axillary lymph node using immunoassay method was positive for estrogen, but PR analysis was negative. Based on this occult breast cancer was the most likely diagnosis, hence the patient was offered radical mastectomy. However, the patient refused the same and she is under the follow-up. Later after eight months of follow-up, she came back with recurrence of the tumour in the same place. There was no evidence of metastasis seen in the follow-up.

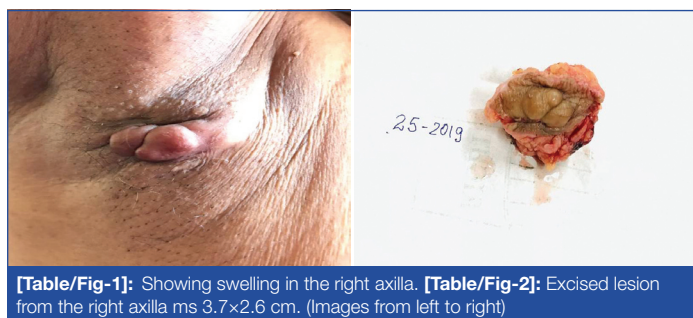micropapillary, and solid patterns [Table/Fig-3]. The tumour cells had clear eosinophilic cytoplasm and uniform low to moderate nuclear grade. By immunohistochemistry, the tumour cells were diffusely and strongly positive for ER and negative for PR receptors [Table/Fig-4]. Patient did not agree for panel of other immunohistochemical markers because of unbearable cost. The final diagnosis of adenocarcinoma metastasis was given to evaluate for primary.



[Table/Fig-3]: (a-c), Tumour arranged in tubular pattern, glandular pattern, solid groups (H&E, 40X), (d) Vesicular nuclei (H&E, 40X).



[Table/Fig-4]: (a, b, and c), Shows strong positivity for ER receptor (IHC, 10X), (d) Immunohistochemical stain showing negative for PR receptor (IHC, 10X).



[Table/Fig-1]: Showing swelling in the right axilla. [Table/Fig-2]: Excised lesion from the right axilla ms 3.7×2.6 cm. (Images from left to right)

Gross examination of the resected specimen showed the tissue with attached skin measuring 3.5×2.7 cm almost the entire specimen was involved by tumour. Histologic examination revealed adenocarcinoma with varied patterns, including glandular, papillary,

## DISCUSSION

Breast carcinoma presenting as axillary lymph node metastasis is very rare and constitutes <1% of all breast cancer [1]. It is defined as carcinoma that has metastasised to the axilla in the absence of mammography or physical findings of disease in the breast. However, it becomes a diagnostic and therapeutic challenge when it presents as axillary metastasis without any obvious primary tumour. Patient with sole clinical presentation of axillary lymph node enlargement is quite challenging both diagnostically and therapeutically [2].

A carcinoma found in the axillary lymph node may be caused by primary carcinoma of heterotrophic glandular tissue or metastatic neoplasm. Heterotrophic glandular tissue is the main culprit for the carcinoma arising from them. However, studies have also shown that there was an absence of heterotrophic glandular tissue in the lymph node which had occult carcinoma [2], which was in present case, besides adenocarcinoma of the breast, many cancers from the lung, thyroid, stomach, colon, rectum, and pancreas can also metastatic to a lymph node. Once the diagnosis of metastatic carcinoma is made on the female patient they are subjected to exhaustive investigation. However, Medina-Franco H and Urist MM, observed that an extensive workup evaluation is not necessary and only axillary dissection may be considered for prognostic indicators as well as local control. However, only with axillary dissection as in present case the patient came back with local recurrence [3].

Most of the patients presenting as axillary lymph node enlargement, the size ranges from 09-25cm and right axilla is the most common axillary lymph node to get enlarged as was in the present case. Initial pathological diagnosis of the biopsied axillary lymph node will not always suggest as breast as its origin, in present case the confirmation was made by immunohistochemistry [4]. The ER and PR staining are the most common immunohistochemical antibodies used to find out the primary site as breast. However, many adenocarcinoma of the lung, gastric, ovary, the endometrium can also metastasis to the axillary lymph node, and if ER/PR is negative it does not exclude the metastasis from another site. However, Kaufmann O et al., in their study observed that expression of Gross Cystic Disease Fluid Protein-15 (GCDFP-15) and/or ER or PR has a sensitivity of 0.83 specificities of 0.93 and predictive accuracy of 0.92 and would help diagnose breast carcinoma metastatic against all other metastatic carcinomas [5]. In present case, ER was positive which correlates with the above study, however authors were not able to process GCDFP-15 as the lesion did not have any porcine differentiation in present case.

Mammoglobin gene is a cancer-specific gene that was discovered two decades ago and only limited studies are available. Mammoglobin is over-expressed in breast cancer compared in normal breast tissue and its expression is not altered at the metastatic (lymph node) site. Bhargava R et al., said that mammoglobin is a more

sensitive marker than GCDFP-15 for breast carcinoma however it lacks the specificity of GCDFP-15 and also said about the pitfall in melanoma, hence its presence with other combination markers would help in the correct diagnosis of metastatic breast carcinoma [5,6]. In the evaluation of the women with occult breast cancer USG, colour doppler USG, breast MCI, Position Emission Tomography (PET), and scintimammography is used [7]. To enable preoperative localisation of primary more sensitive investigations like MRI may be helpful. Watchful waiting would be one of the treatment options as to when patients present with breast tumour mastectomy may be performed. However, in present case watchful waiting led to the recurrence of a similar lesion in the axilla [8]. A 10 year survival rate for patients with occult breast cancer is 50-70% [9]. The survival of the patient is independent of the primary tumour in mastectomy specimen and ER status would be a good prognostic variable [10]. The treatment options like mastectomy and breast conservative treatment such as limited resection and/or radiation/chemotherapy have no statistically significant outcome [9].

## CONCLUSION(S)

The primary breast cancer remains clinically and radiologically occult, however histological and immunohistochemical findings are fundamental to identify its origin. Hence, it is important to know the histology of the lesion along with other supporting investigations which are more sensitive to make a correct diagnosis.

## REFERENCES

- [1] Ouallaa K, Elm'rabet F, Arifi S, Mellas N, Melhouf MA, Bouhafa T, et al. Occult primary breast cancer presenting with axillary nodal metastasis: Report of 3 cases. *J Clin Gynecol Obstet.* 2012;1:85-88.
- [2] Abe H, Naitoh H, Umeda T, Shiomi H, Tani T, Kodama M, et al. Occult breast cancer presenting axillary nodal metastasis: A case report. *Jpn J Clin Oncol.* 2000;30:185-87.
- [3] Medina-Franco H, Urist MM. Occult breast carcinoma presenting with axillary lymph node metastases. *Rev Invest Clin.* 2002;54:204-08.
- [4] Patel J, Nemoto T, Rosner D, Dao TL, Pickren JW. Axillary lymph node metastasis from an occult breast cancer. *Cancer.* 1981;47:2923-27.
- [5] Kaufmann O, Deidesheimer T, Muehlenberg M, Deicke P, Dietel M. Immunohistochemical differentiation of metastatic breast carcinomas from metastatic adenocarcinomas of other common primary sites. *Histopathology.* 1996;29:233-40.
- [6] Bhargava R, Beriwal S, Dabbs DJ. Mammoglobin vs GCDFP-15 an immunohistologic validation survey for sensitivity and specificity. *Am J Clin Pathol.* 2007;127:103-13.
- [7] Guo R, Lu G, Qin B, Fei B. Ultrasound imaging technologies for breast cancer detection and management: A review. *Ultrasound Med Biol.* 2017;44:01-34.
- [8] Sakorafas GH, Tsiotou AG. Occult breast cancer: A challenge from a surgical perspective. *Surg Oncol.* 1999;8:27-33.
- [9] Baron PL, Moore MP, Kinne DW, Candela FC, Osborne MP, Petrek JA. Occult breast cancer presenting with axillary metastases updated management. *Arch Surg.* 1990;125:210-14.
- [10] Song X, Ma J, Zhang H, Zhang Q. Prognostic significance of the primary tumour site and immune indexes in patients with oestrogen receptor-positive, human epidermal growth factor receptor-2-negative breast cancer. *Gland Surg.* 2020;9:1450-68.

### PARTICULARS OF CONTRIBUTORS:

1. Pathologist, Department of Pathology, National Institute of Unani Medicine, Bengaluru, Karnataka, India.
2. Postgraduate Scholar, Department of Pathology, National Institute of Unani Medicine, Bengaluru, Karnataka, India.

### NAME, ADDRESS, E-MAIL ID OF THE CORRESPONDING AUTHOR:

Dr. Renuka Bangalore Nagaraj,  
Pathologist, Department of Pathology, National Institute of Unani Medicine,  
Bengaluru, Karnataka, India.  
E-mail: renushivu@yahoo.com

### AUTHOR DECLARATION:

- Financial or Other Competing Interests: None
- Was informed consent obtained from the subjects involved in the study? Yes
- For any images presented appropriate consent has been obtained from the subjects. Yes

### PLAGIARISM CHECKING METHODS: [Jain H et al.]

- Plagiarism X-checker: Jun 22, 2021
- Manual Googling: Jul 09, 2021
- iThenticate Software: Jul 08, 2021 (20%)

### ETYMOLOGY: Author Origin

Date of Submission: **Jun 22, 2021**  
Date of Peer Review: **Jul 01, 2021**  
Date of Acceptance: **Jul 10, 2021**  
Date of Publishing: **Aug 01, 2021**